

Elbow Dysplasia

Elbow dysplasia is a genetic disorder that occurs when the bones of the elbow joint fail to develop properly, resulting in misalignment, uneven joint surfaces and stress points. This problem occurs in young dogs, especially large breeds such as Labrador Retrievers and Rottweilers, although it can occur in other breeds as well. Since it is hereditary, care should be taken to avoid breeding dogs with elbow dysplasia.

Symptoms of this condition include forelimb lameness and sometimes swelling of the elbow. The extent of symptoms and discomfort depends upon the severity of the disease and your dog's tolerance to pain. In many animals, the condition occurs in both elbows.

The elbow is made up of three bones: the humerus, radius and ulna (fig. 1 and fig. 2). During a dog's rapid growth phase, usually between four and nine months of age, these bones may fail to grow in harmony. The result is uneven joint surfaces and "stress" points in the elbow joint.

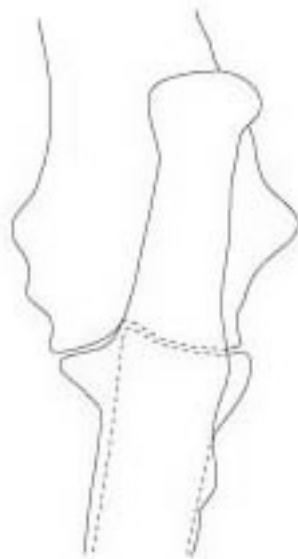

Fig. 1

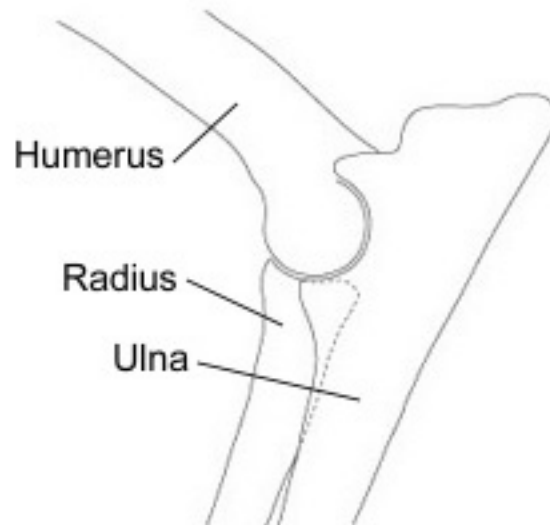


Fig.2

At the very least, this condition predisposes the elbow to premature wear. In many cases, the stress points become serious enough to cause bone or cartilage fragments to break off. These fragments in the joint feel similar to a stone in your shoe. They increase discomfort and often hasten the onset of arthritis. The most common fragments occur in the areas of the anconeal process (fig.3) medial coronoid process (fig 4a) and on the medial humeral condyle (fig. 4b). These conditions are called Ununited Anconeal Process, Fragmented Coronoid Process and Osteochondrosis of the Elbow.

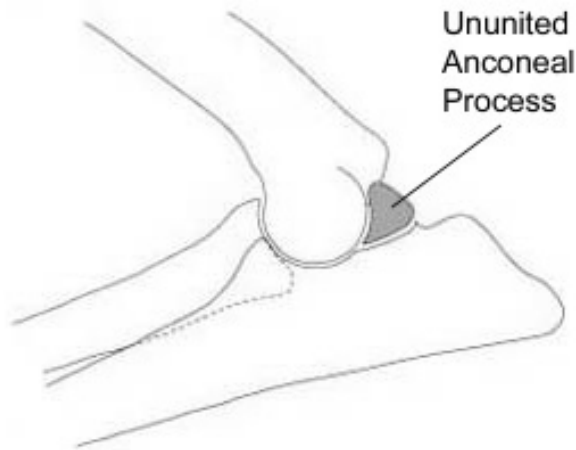


Fig. 3

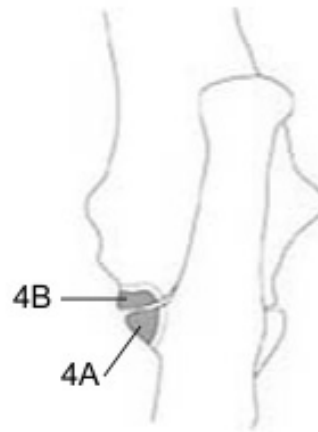


Fig. 4

4A - Fragmented Coronoid Process
4B - Osteochondrosis of the Elbow

Diagnosis:

Since Elbow Dysplasia is not the only cause of forelimb lameness, it is important to have your pet carefully examined to ensure that an accurate diagnosis is made and appropriate treatment is instituted.

A physical examination is very useful in localizing the cause of lameness. By observing your dog move and by palpating the limb(s), the veterinarian is often able to isolate the specific bone or joint responsible for the lameness. Radiographs (x-rays) will show if any bone fragments are present within the joint and whether or not arthritis has developed.

Early in the disease process, bone and cartilage fragments may not be readily visible on the radiographs. In these cases, additional tests such as a nuclear medicine bone scan can be of great help. This special imaging technique detects joint inflammation at a very early stage. Once the diagnosis is established, treatment can be initiated.

Treatment:

The treatment of Elbow Dysplasia depends on the severity of the disease and at what stage it is diagnosed. If the disease is recognized in a young dog and the elbow has minimal arthritic changes, surgical intervention can help. Two types of surgery are available. The goals of surgery are first, to remove the sources of joint irritation and, with the second more aggressive surgery, to improve joint mechanics by improving bone alignment. Even after surgery, some dogs may continue to have a little lameness and may need to be restricted from heavy exercise, i.e. frisbee playing.

The first technique, where no bone is cut, is recommended for early stage Elbow Dysplasia. This surgery explores the joint, removing any fragments in the process. It eliminates the "stone-in-the-

shoe" effects of the disease, but does little to address the underlying bony malalignment of the elbow. However, in milder cases, this technique has proven adequate to relieve discomfort and swelling. Following surgery, your dog should have restricted activity for approximately four weeks.

When more severe malalignment occurs, the surgeon cuts the ulna bone to expose the entire joint, removing any fragments and adjusting the alignment of the bones. The ulna is then repaired with stainless steel pins, and wire (fig.5). The pins and wire remain in place as long as they do not move or otherwise irritate your pet. Aftercare is more involved with this procedure, requiring restricted activity for six to eight weeks. Complete instructions for home care are provided and your dog's recovery progress is checked at regular intervals following surgery.

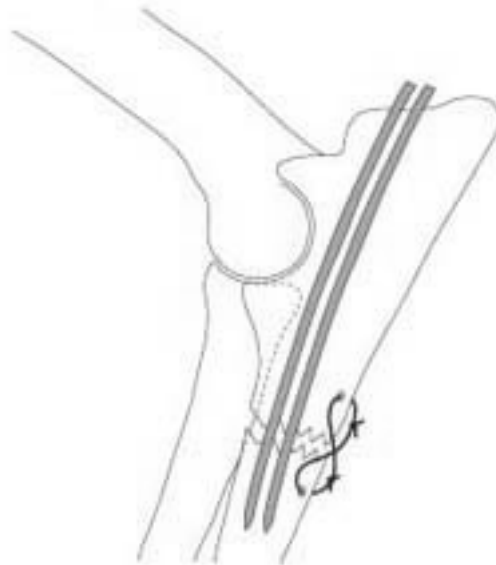


Fig. 5

With each of these techniques, there is approximately a 70 percent chance of significant improvement. Some dogs may continue to have lameness and need to be restricted from heavy activity following recovery from surgery.

In some cases of Elbow Dysplasia, dogs may not show symptoms of this disease until their later years, after they have developed significant arthritis. Sometimes these dogs become suddenly lame and very often have strained or sprained their arthritic elbow or have developed secondary infections in these joints. Radiographs (x-rays) taken at that time often reveal long-term changes in their elbows.

A joint tap (where a sample of joint fluid is removed) is recommended in these older arthritic joints to differentiate between simple arthritis and secondary infection. Whatever the cause, these



VCA Animal Specialty Group

5610 Kearny Mesa Rd., Suite B | San Diego, CA 92111
858-560-8006 | www.vcaanimalspecialtygroup.com

old, arthritic joints are best treated medically with various forms of pain relievers, joint lubricating drugs and arthritis medications.

Elbow Registry:

Recently, the Orthopedic Foundation of Animals (OFA) established a registry for dogs whose elbows show no radiographic signs of Elbow Dysplasia. The OFA provides a similar certification for Hip Dysplasia. By certifying dogs with good elbows for breeding, the OFA hopes that the incidence of Elbow Dysplasia will decrease. Your veterinarian can provide you with information on the elbow and hip certification process.

Summary:

Elbow Dysplasia is being diagnosed more frequently because of an enhanced awareness of the disease process and improved diagnostic techniques. Early diagnosis is essential if surgical treatment is to be of value in relieving discomfort and removing some of the sources of irritation that can lead to arthritis.

As with Hip Dysplasia, early radiographic screening of elbow joints is recommended. This procedure very often can be done at the time of spaying or neutering (typically at six months of age). Since the problem is genetic in nature, dogs with Elbow Dysplasia should not be used for breeding.

VCA Animal Specialty Group will be happy to answer your questions about the screening and treatment of Elbow Dysplasia. We have worked with family veterinarians since 1982, providing consultations, thorough evaluations and subsequent treatment of Elbow and Hip dysplasia.